
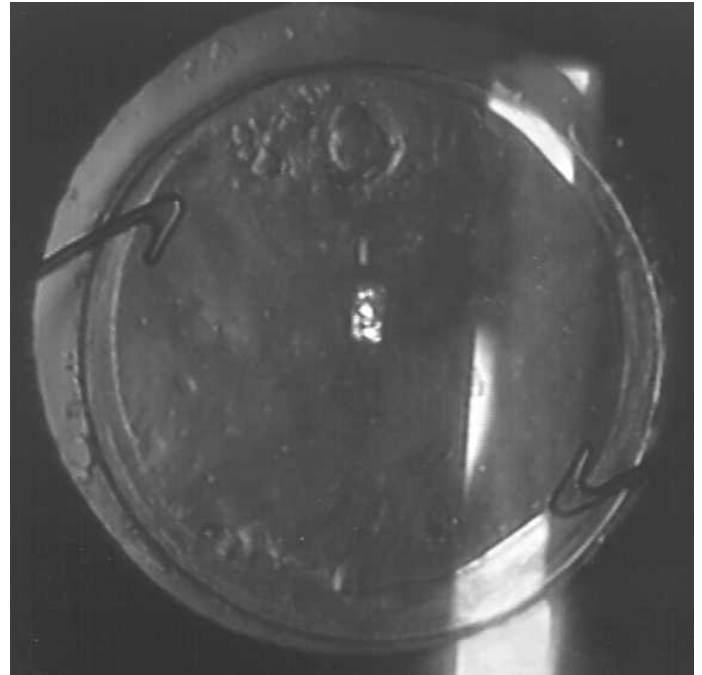


How to do a Nd:YAG Laser capsulotomy on Mr. Lee's Patients

1. Informed consent on single consent sheet ideally do on listing.
2. Ensure given patient information handout from Practice Manager.
3. - Ideally give patients dilating drops to take at home so they come ready dilated.
4. Proxymethocaine.
5. Check make of Intra-Ocular Lens (IOL) - If plate haptic need to do a Circular capsulotomy.
6. Staar AQ2010V, all 3 piece lenses use a cross technique.
7. Clean the Abraham Lens with alcohol swab and place in Hydrochloride for 5 minutes before washing in sterile water.
8. Check power settings. Reset counters to zero.
9. Ensure one shot and not left on multiple pulse.
10. Ensure Defocused by +1.50 dioptres so that the Nd:YAG Laser explosion occurs behind the lens. 2.50 is probably too much.
11. Start with around 1.5 mj adjusting according to how thick the capsule is and the response, less for very thin more for very thick.
12. Start centrally, with red aiming beam
13. Apply the Abrahams Nd:YAG Laser lens with a new tube of Viscotears (or a new one that afternoon).
14. Use fixation pointer for other eye.
15. Ensure the forehead is firmly placed against the bar.
16. Ensure any observers have the correct safety goggles.
17. Ensure two red aiming beam is just focused just behind the capsule and fire.
18. This should cut the capsule without any pits.
19. Adjust the power according to the response.
20. IF any pits occur you are probably focusing into the lens or the patient is moving.
21. Then proceed up and down cutting the capsule
22. Then proceed left and right to complete the Cross.
23. Ensure there are no small strands holding the two edges together.
24. Give Diamox (Acetazolamide) 250mg SR one tablet
25. Give g. Predsol qds (quarter die sumendus - four times per day) for one week.
26. Do not give a follow up appointment unless for other conditions or a problem.



27. Record in Laser log book and Notes

28. Clean the Lens with alcohol wipe and soak in Hydrochloride solution.

You should then have a wide open capsule for the patient to see. There should be no or at worst only one or two pits or damage to the lens. You do see patients with multiple pits in their lenses, and this is either due to poor technique or a badly focused laser. By and large they cause few problems but large numbers can cause glare etc..

Other Techniques

1. For Staar Toric or other plate haptics.
2. Do not do a Cross capsulotomy.
3. Do a spiral circular one starting in the centre and working out in a spiral fashion to essentially produce a Posterior circular rhexis.
4. Avoid dinner plates or complete circles as these can produce large floaters that move up and down which can be very troublesome.

Mr. Nicholas Lee 2011

Lead Ophthalmic Clinician at The Hillingdon Hospital

Consultant Ophthalmologist at The Western Eye Hospital

Mobile 07956 263804. Fax 01895 835404